

## Parts of the Horse

### Parts of the Horse

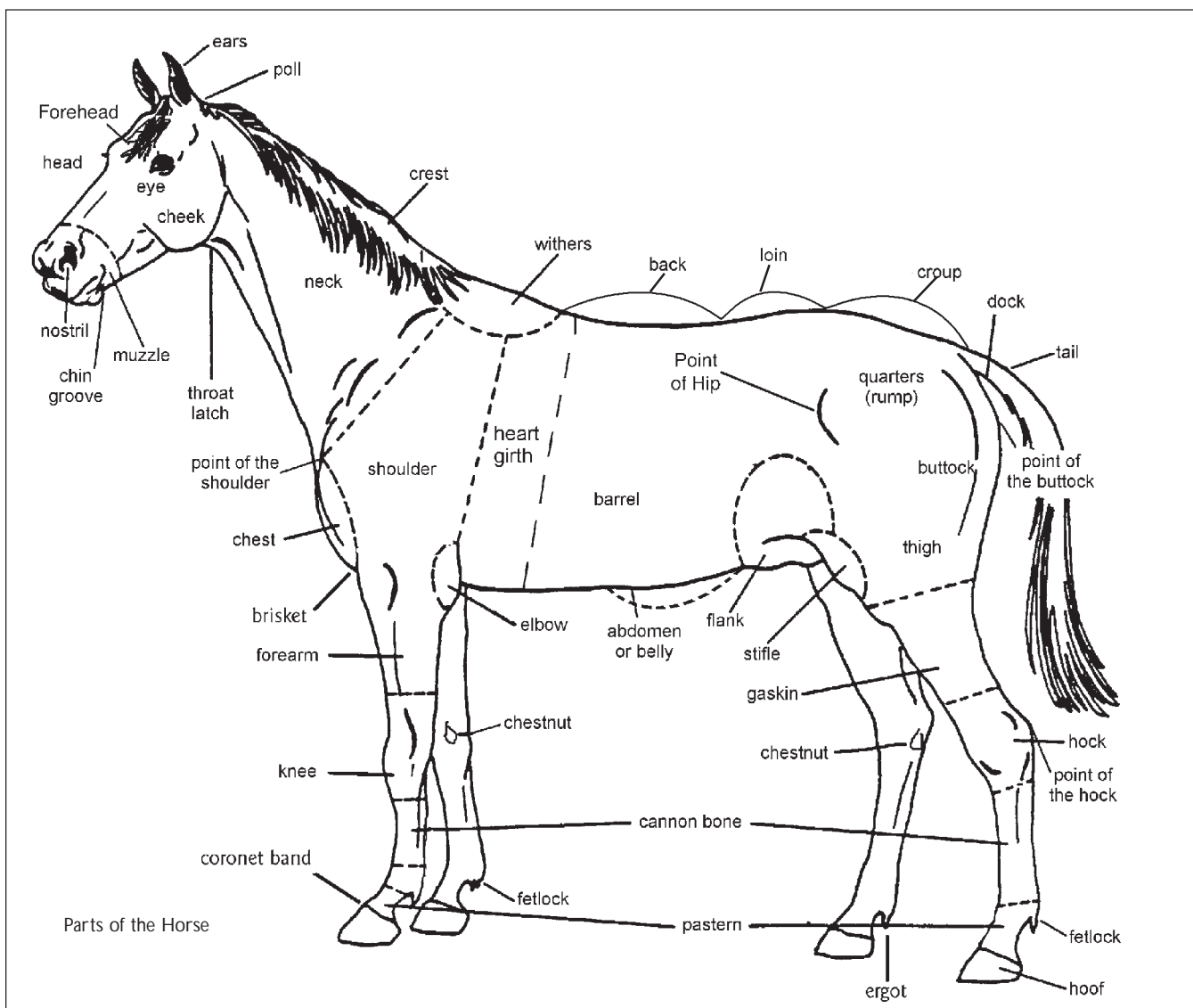
**Abdomen or Belly** The broad area underneath the horse between the elbow and the flank.

**Back** The horse's back runs from the withers to the loin. This contains part of the spinal column.

**Barrel** The large area below the back in the general vicinity of the rib cage. This is where the heart, lungs and stomach of the horse are housed.

**Brisket** The area directly between the forelegs at the front of the abdomen.

**Buttock** The muscled area below the dock and above the thigh.



## 4 - H H o r s e P r o j e c t M a n u a l - P a r t s o f t h e H o r s e

---

**Cannon Bone** The long bone between the knee or hock and the fetlock joint.

**Cheek (Jowls)** Distinct rounded bones on the sides of the horses jaw.

**Chest** The muscled area at the front of the horse below the neck attachment down to the legs. The width, depth and muscling of the chest will influence how well the horse can move. A chest that is too wide produces a labouring, waddling stride and a chest that is too narrow may interfere with the horse's travelling.

**Chestnut** A horny growth on the inside of each leg. They are above and on the inside of the knee of the front leg and below and on the inside of the hock of the back leg.

**Chin Groove** The hollow between the chin and the branches of the jaw.

**Coronet/Coronary Band** Area at the bottom of the pastern where hair stops and hoof growth begins.

**Crest** The top line of the neck.

**Croup** The area at the top of the rump and in front of the tail. It extends from the highest part of the hip to the tail.

**Dock** The solid part of the horse's tail, containing the tailbone.

**Ears** Two ears located on the top of the horse's head.

**Elbow** The joint at the top of the forearm.

**Eyes** Two eyes located on the sides of the skull.

**Fetlock** The joint between the long pastern bone and the cannon.

**Flank** The region between the barrel and the hindquarters.

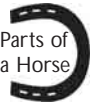**Forearm** The upper part of the foreleg, between the elbow and the knee.

**Gaskin** A muscled area of the hind leg, above the hock and below the stifle.

**Head** Includes the area from the muzzle to the poll.

**Heart Girth** A line drawn around the barrel just behind the elbow and withers.

**Hock** The joint of the hind leg below the gaskin and above the cannon bone.



# 4 - H H o r s e P r o j e c t M a n u a l - P a r t s o f t h e H o r s e

---

## Parts of the Horse

(continued)

**Hoof Wall** A horny covering from the coronet band to the ground protecting the sensitive part of the foot.

**Knee** The joint of the front leg below the forearm and above the cannon bone.

**Loin** The short muscled area joining the back to the croup.

**Muzzle** Describes the area including the nostrils, chin and mouth.

**Neck** Muscled area from the poll to the withers attaching the head to the body.

**Nostril** The part of the muzzle through which the horse breathes.

**Pastern** The area above the coronet band and below the fetlock joint.

**Point of the Buttock** Is the highest point of the buttock at the extreme rear of the animal.

**Point of the Hip** The bony point lying just forward and below the croup.

**Point of the Hock** The most prominent part of the hock at the back.

**Point of the Shoulder** The bony point at the extreme lower end of the shoulder blade, just above and to the side of the chest.

**Poll** A point between the ears at the top of the head where the head joins the neck.

**Shoulder** The area of the horse's front quarters where the front leg is attached to the body with muscles and tendons.

**Stifle** Is a joint at the front of the thigh in the flank area.

**Thigh** The large muscled area below the croup, below and in front of the buttock and behind the stifle joint.

**Throat Latch** The area behind the jaw where the head attaches to the neck.

**Upper Arm** The area above the elbow to the point of the shoulder.

**Withers** The prominent ridge near the base of the mane where the neck and back join.